

# NIDEK'S QUEST: THE NEW EC-5000 EXCIMER LASER PLATFORM

BY JAMES S. LEWIS, MD

## WHY DID YOU CHOOSE NIDEK FOR YOUR EXCIMER LASER UPDATE?

The Quest EC-5000 is the latest incarnation of NIDEK's workhorse line of excimer lasers. NIDEK remains the only manufacturer to remain click-fee free. During the past 17 years, high-volume surgeons and value-based practices have gravitated to NIDEK because there are no user fees, no patient interfaces, no key cards, and no usage charges of any kind.

Two years ago, I purchased the Quest system because NIDEK had leapfrogged the competition's population optimized wavefront technology. Their device-specific customized aspheric treatment zone (CATz) is a next-generation ablation pattern that leverages peripheral corneal tissue to achieve a final prolate cornea shape free from spherical aberration. CATz "shot-files" are based on the patient's refraction and topography. Waring and Dougherty,<sup>1</sup> in the FDA-filings for this device, proved a statistically significant reduction in night driving complaints post-operatively when compared with the patient's best corrected pre-operative state. These findings, combined with an industry leading percentage<sup>2</sup> of uncorrected 20/15 results post-LASIK, establishes Quest and the CATz algorithm as a performance breakthrough in excimer ablation technology.

## DOES NIDEK HAVE TOPOGRAPHICALLY-GUIDED ABLATION?

NIDEK's CATz algorithm can regularize corneal topography over a broad range of refractive errors. For appropriate cases, CATz adds a distinct topography-guided segmental ablation to regularize the resultant corneal shape. This approach enlarges the effective optical zone and preserves a prolate corneal curvature. CATz technology allows the LASIK surgeon to produce best-in-class visual results for both standard refractive cases and patients with mild, non-pathologic irregular astigmatism. Furthermore, CATz can be used for highly aberrated eyes, including patients status-post keratoplasty. I have treated a variety of patients with untoward visual phenomenon resulting from significant corneal scarring, decentered ablations, small optical zones, central islands, and flap injury. I have also addressed irregular astigmatism from DLK, epithelial ingrowth, corneal infection, complicated cataract surgery and excessive limbal relaxing incisions.

## HOW DO THE SURGEON AND LASER INTERFACE?

NIDEK's bundled Final Fit Program drives the Quest platform. Physicians use this Window's-based software to organize patients,

consolidate clinical information, construct surgical strategies, simulate refractive results and assess outcomes. The technology enhances the creative process and empowers the LASIK surgeon.

## DESCRIBE USE OF CATZ WITH A TYPICAL CASE

A 28-year-old patient presented with mild irregular astigmatism (Figure 1) and a warning from another LASIK center that a 20/20 result may not be feasible. I constructed a surgical plan addressing sphere, cylindrical, and irregularity. Final Fit generated the topography guided ablation pattern (Figure 2). This patient gained a line of BSCVA.

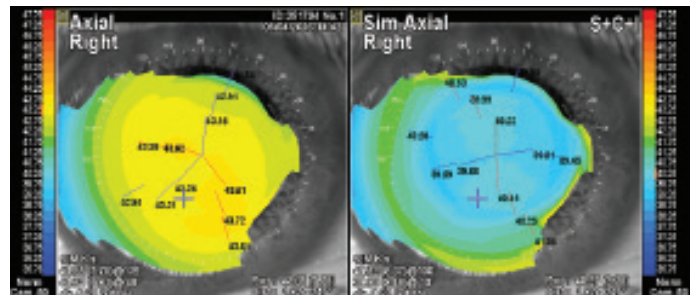


Figure 1. The axial topography on the left shows subtle irregular astigmatism. The right image is a simulated axial topography following CATz.

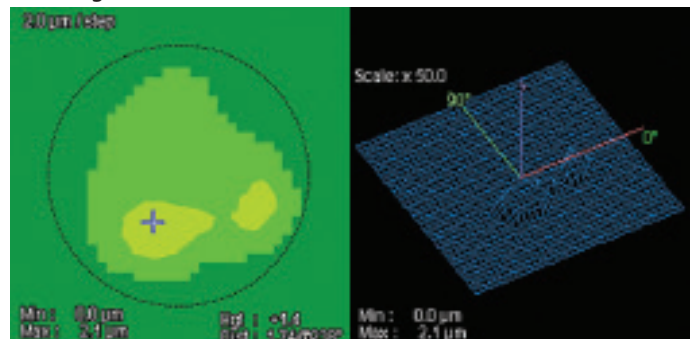


Figure 2. The map on the left shows the proposed tissue removal. The 3D mesh on the right shows how CATz plans to regularize the corneal topography.

## DESCRIBE USE OF CATZ IN MORE DIFFICULT CASES

A 56-year-old post-LASIK ectasia patient had uncomplicated penetrating keratoplasty in each eye. Acuity was limited in one eye by significant irregular astigmatism (Figure 3) and a reluctance to wear an RGP. PRK with mitomycin was performed using the

# NIDEK'S QUEST: THE NEW EC-5000 EXCIMER LASER PLATFORM

CATz algorithm. The patient, whose topography is shown in Figure 3, enjoys 20/25 acuity with spectacles 1 year later.

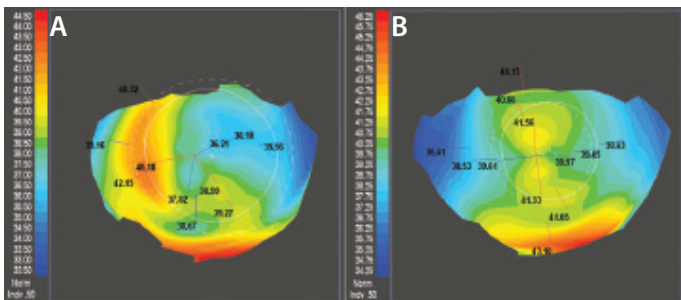


Figure 3. The left topography shows significant irregular astigmatism following full thickness penetrating keratoplasty (A). On the right is the post-operative topography one year after CATz-driven PRK (B). Best corrected spectacle improved from 20/40- to 20/25.

A 55-year-old, who had LASIK in 1999, tolerated limited spectacle acuity, glare, haloes, starbursts, and driving difficulties for over a decade. The preoperative topography shown in Figure 4 explains these complaints. I performed topographically guided surgery and consequently enlarged the effective optical zone. The patient recovered 20/20 spectacle acuity and experienced a significant reduction in glare, haloes, starbursts, and night driving issues. I have successfully treated several of my original LASIK patients who tolerated residual visual phenomenon from early generation excimer technology. Quest allows the LASIK surgeon to address an

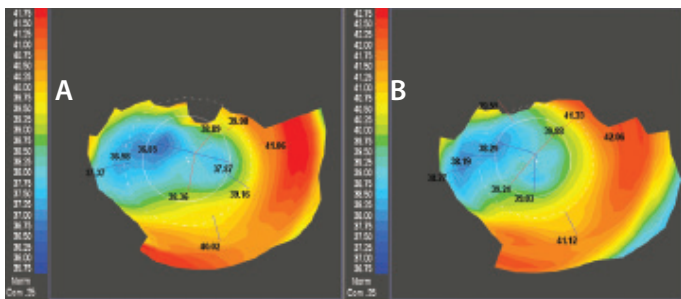


Figure 4. A moderately decentered ablation pattern from LASIK fifteen years ago is shown on the left (A). Topography after CATz shown on the right demonstrates an enlarged optical zone (B). BSCVA acuity improved from 20/40 to 20/20.

entire class of patient who, until now, have been underserved.

A distraught 29-year-old patient presented following complicated femtosecond flap creation and subsequent LASIK elsewhere. The novice surgeon had ablated tissue from both the stromal bed and the posterior flap. The resulting topography, shown in Figure 5, shows a 9.0 D astigmatic gradient across the visual axis. Two rounds of topo-guided surface ablation improved the topography which can be seen in the adjacent image.

Because correction of this patient required a segmental ablation

of 20 microns (Figure 6), surgery was divided into two sessions 9 months apart. This patient gained a line of vision and now successfully wears contact lenses.

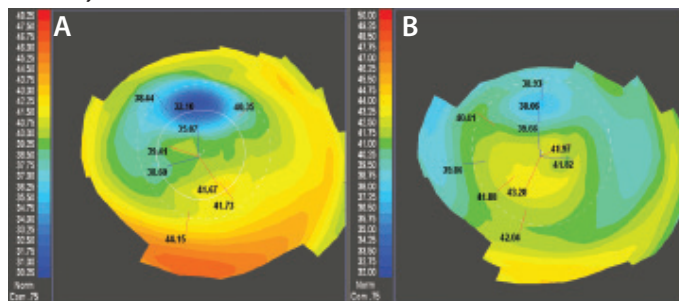


Figure 5. The left image shows a highly aberrated cornea following complicated LASIK (A). Two courses of CATz-driven PRK resulted in the improved topography shown on the right (B). The patient gained a line of BSCVA and can now tolerate a contact lens.

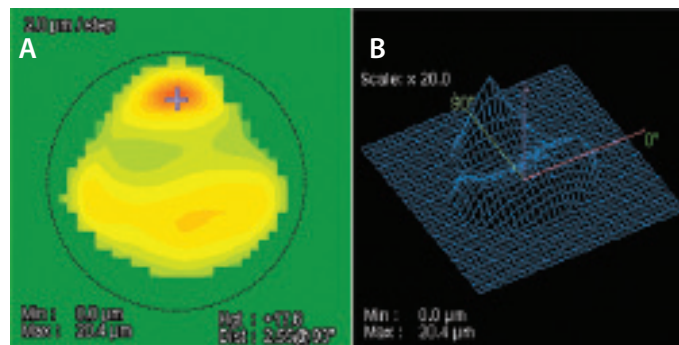


Figure 6. NIDEK's Final Fit Software shows the theoretical ablation map needed to regularize the astigmatism in this challenging case (A). The image on the right demonstrates the tissue elevation addressed in 3D (B).

## SUMMARIZE YOUR EXPERIENCE WITH THIS NEW PLATFORM

NIDEK's Quest introduces CATz and Final Fit to the refractive surgeon. CATz maintains a prolate cornea and reduces spherical aberrations. When indicated, its segmental ablation pattern can extend these outstanding visual results to patients with modest irregularities in corneal astigmatism. Final Fit enables the surgeon to design the ideal procedure for every clinical scenario. In my opinion, Quest has expanded and energized LASIK.

1. Waring G, Dougherty PJ, Chayet A, et al. Topographically guided LASIK for myopia using the Nidek CXII Customized Aspheric Treatment Zone (CATz). *Trans Am Ophthalmol Soc.* 2007;105: 240-248.
2. Blanton CL. Meta-analysis of six excimer laser platforms for safety and efficacy in myopic laser-assisted in situ Keratomileusis. *US Ophthalmic Review.* 2015;8(1):23-29.

James Lewis, MD, is a tertiary care anterior segment specialist who has practiced in Elkins Park, Pa., for 27 years. He purchased his first NIDEK in 1999 and has always had an interest in treating highly aberrated corneas with the excimer laser. Dr. Lewis reports no relevant financial disclosures. He may be reached at [Jslewis@jameslewismd.com](mailto:Jslewis@jameslewismd.com).

